

Introduction to Freshwater Fish Parasites ¹

RuthEllen Klinger and Ruth Francis Floyd²

Introduction

Fish culture as a hobby or business is well established in Florida. Increased interest in fish culture has also increased awareness of and experience with parasites that affect fish health, growth, and survival. Information provided in this circular is intended for the novice fish culturist as a guide to common parasites of freshwater fish. Identification of parasites and their basic treatment is included; however, this information should not be substituted for consultation with an experienced fish health professional.

NOTE: Mention of drugs or chemicals in this publication in no way represents a recommendation for their use, nor does it imply that they are approved for use by the Food and Drug Administration or the Environmental Protection Agency.

This circular covers the following topics and species:

I. Identification of a Parasitic Problem

II. Protozoa

- A. Ciliates
 - 1. *Ichthyophthirius multifiliis*
 - 2. *Chilodonella*
 - 3. *Tetrahymena*
 - 4. *Trichodina*
 - 5. *Ambiphyra*
 - 6. *Apiosoma*
 - 7. *Epistylis*

- 8. *Capriniana*
- 9. Treatment of Ciliated Protozoan Infections
- B. Flagellates
 - 1. *Hexamita / Spirotrunculus*
 - 2. *Ichthyobodo*
 - 3. *Piscinoodinium*
 - 4. *Cryptobia*
- C. Myxozoa
- D. Microsporidia
- E. *Coccidia*

III. Monogenean Trematodes

IV. Digenean Trematodes

V. Nematodes

- A. *Camillanus*
- B. *Capillaria*
- C. *Eustrongylides*

VI. Cestodes

VII. Parasitic Crustacea

- A. *Ergasilus*
- B. *Lernaea*
- C. *Argulus*

VIII. Leeches

IX. Conclusion

1. This document is CIR716, one of a series of the Fisheries and Aquatic Sciences Department, Florida Cooperative Extension Service, Institute of Food and Agricultural Sciences, University of Florida. First published March 1987 by Frederick J. Aldridge and Jerome V. Shireman; Reprinted April 1994. Reviewed May 2009 and June 2013. Visit the EDIS website at <http://edis.ifas.ufl.edu>.

2. RuthEllen Klinger, biological scientist, Department of Large Animal Clinical Sciences (College of Veterinary Medicine) and Ruth Francis Floyd, associate professor, Department of Fisheries and Aquatic Sciences (Institute of Food and Agricultural Sciences), Department of Large Animal Clinical Sciences (College of Veterinary Medicine), Cooperative Extension Service, Institute of Food and Agricultural Sciences, University of Florida, Gainesville, 32611.

Identification of a Parasitic Problem

A common mistake of fish culturists is misdiagnosing disease problems and treating their sick fish with the wrong medication or chemical. When the chemical doesn't work, they will try another, then another. Selecting the wrong treatment because of misdiagnosis is a waste of time and money and may be more detrimental to the fish than no treatment at all. The majority of fish parasites can only be identified by the use of a microscope. If a microscope is unavailable, or the person using it has no previous experience with one, the diagnosis is difficult and questionable. Successful fish culturists learn by experience. Newcomers to the field need to learn the fundamentals of diagnostic procedures and how to use a microscope to identify parasites by attending short training courses. The following descriptions of common parasites can be used as references for understanding a professional diagnostic report or as a quick reference for the experienced fish culturist.

Protozoa

Most of the commonly encountered fish parasites are protozoans. With practice, these can be among the easiest to identify, and are usually among the easiest to control. Protozoans are single-celled organisms, many of which are free-living in the aquatic environment. Typically, no intermediate host is required for the parasite to reproduce (direct life cycle). Consequently, they can build up to very high numbers when fish are crowded causing weight loss, debilitation, and mortality. Five groups of protozoans are described in this publication: ciliates, flagellates, myxozoans, microsporidians, and coccidians. Parasitic protozoans in the latter three groups can be difficult or impossible to control as discussed below.

Ciliates

Most of the protozoans identified by aquarists will be ciliates. These organisms have tiny hair-like structures called cilia that are used for locomotion and/or feeding. Ciliates have a direct life cycle and many are common inhabitants of pond-reared fish. Most species do not seem to bother host fish until numbers become excessive. In aquaria, which are usually closed systems, ciliates should be eliminated. Uncontrollable or recurrent infestations with ciliated protozoans are indicative of a husbandry problem. Many of the parasites proliferate in organic debris accumulated in the bottom of a tank or vat. Ciliates are easily transmitted from tank to tank by nets, hoses, or caretakers' wet hands.

Symptoms typical of ciliates include skin and gill irritation displayed by flashing, rubbing, and rapid breathing.

ICHTHYOPHTHIRIUS MULTIFILIIS

The disease called "Ich" or "white spot disease" has been a problem to aquarists for generations. Fish infected with this organism typically develop small blister-like raised lesions along the body wall and/or fins. If the infection is restricted to the gills, no white spots will be seen. The gills will appear swollen and be covered with thick mucus. Identification of the parasite on the gills, skin, and/or fins is necessary to conclude that fish has an "ich" infection. The mature parasite (Figure 1) is very large, up to 1000 μm in diameter, is very dark in color due to the thick cilia covering the entire cell, and moves with an amoeboid motion. Classically, *I. multifiliis* is identified by its large horseshoe-shaped macronucleus. This feature is not always readily visible, however, and should not be the sole criterion for identification. Immature forms of *I. multifiliis* are smaller and more translucent in appearance. Some individuals have suggested that the immature forms of *I. multifiliis* resemble *Tetrahymena*. Fortunately, scanning the preparation will usually reveal the presence of mature parasites and allow confirmation of the diagnosis.

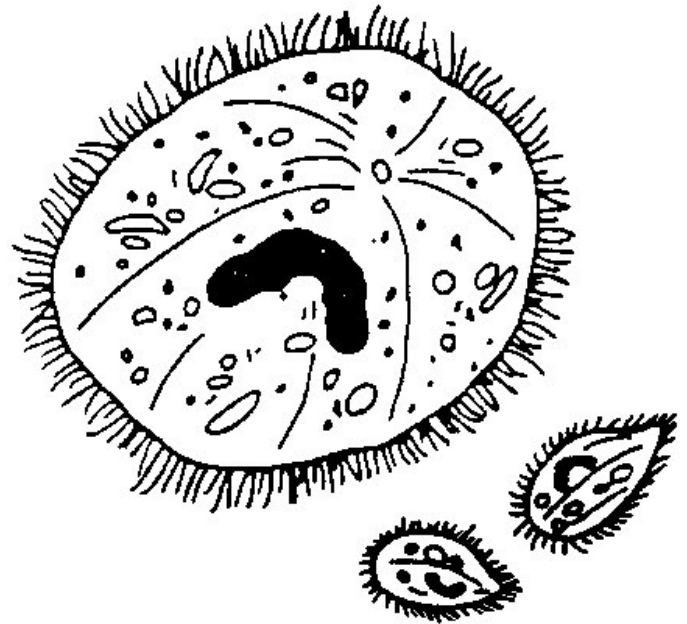


Figure 1.

If only one parasite is seen, the entire system should be treated immediately. "Ich" is an obligate parasite and capable of causing massive mortality within a short time. Because the encysted stage (Figure 2) is resistant to chemicals, a single treatment is not sufficient to treat "Ich".

Repeating the selected treatment (Table 1) every other day (at water temperatures 68--77°F) for three to five treatments will disrupt the life cycle and control the outbreak. Daily cleaning of the tank or vat helps to remove encysted forms

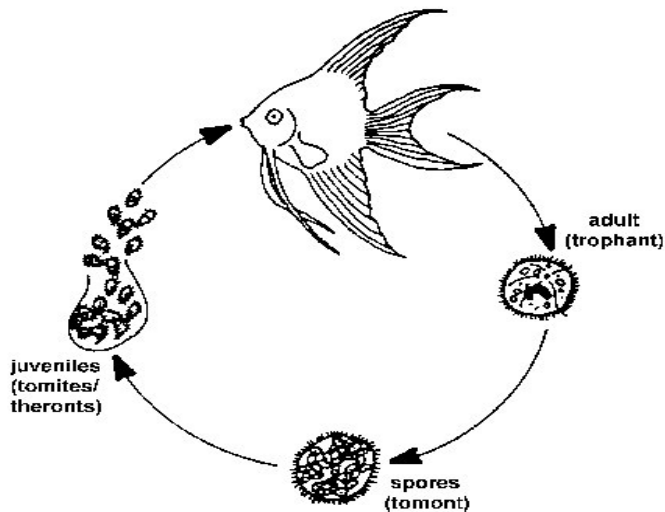


Figure 2.

from the environment. For more information, see Extension Circular 920, *Ichthyophthirius multifiliis* (White Spot) Infections of Fish.

CHILODONELLA

Chilodonella is a ciliated protozoan that causes infected fish to secrete excessive mucus. Infected fish may flash and show similar signs of irritation. Many fish die when infestations become moderate (five to nine organisms per low power field on the microscope) to heavy (greater than ten organisms per low power field). *Chilodonella* is easily identified using a light microscope to examine scrapings of skin mucus or gill filaments. It is a large, heart-shaped ciliate (60 to 80 μ m) with bands of cilia along the long axis of

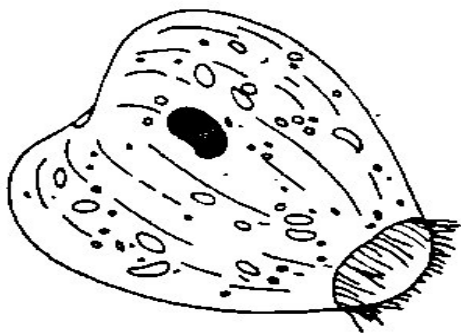


Figure 3.

the organism (Figure 3). The organism is easily recognized at 100X magnification. *Chilodonella* can be controlled with any of the chemicals listed in Table 1, and one treatment is usually adequate. *Chilodonella* has been eliminated in tanks using recirculating water systems by maintaining 0.02% salt solution.

TETRAHYMENA

Tetrahymena is a protozoan commonly found living in organic debris at the bottom of an aquarium or vat. *Tetrahymena* is a teardrop-shaped ciliate (Figure 4) that moves along the outside of the host. The presence of *Tetrahymena* on the body surface in low numbers (less than five organisms per low power field) is probably not significant. It is commonly found on dead material and is associated with high organic loads. Therefore, observing *Tetrahymena* on fish, which have been on the tank bottom, does not imply the parasite is the primary cause of death. One treatment of a chemical listed in Table 1 should be adequate for control.

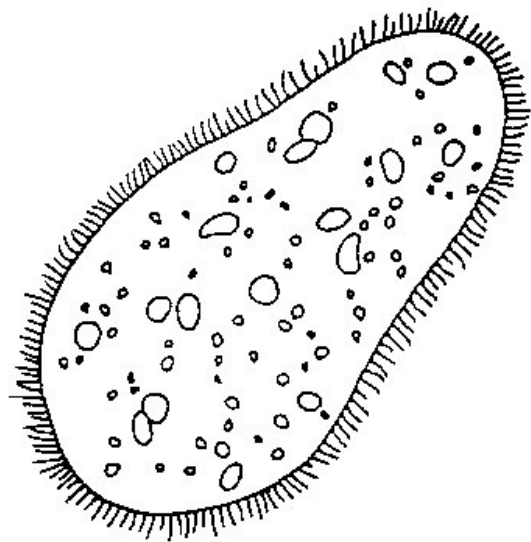


Figure 4.

Identification of *Tetrahymena* internally is a significant but untreatable problem. A common site of internal infection is the eye. Affected fish will have one or both eyes markedly enlarged (exophthalmia). Squash preparations made from fresh material reveal large numbers (≥ 10 per low power field) of *Tetrahymena* associated with fluids in the eye. Fish infected with *Tetrahymena* internally should be removed from the collection and destroyed.

TRICHODINA

Trichodina is one of the most common ciliates present on the skin and gills of pond-reared fish. Low numbers (less than five organisms per low power field) are not harmful, but when fish are crowded or stressed, and water quality deteriorates, the parasite multiplies rapidly and causes serious damage. Typically, heavily infested fish do not eat well and lose condition. Weakened fish become susceptible to opportunistic bacterial pathogens in the water. *Trichodina* can be observed on scrapings of skin mucus, fin, or on gill filaments. Its erratic darting movement and the presence of a circular, toothed disc within its body (Figure 5) easily identify it. *Trichodina* can be controlled with any of the treatments from Table 1. One application should be sufficient. Correction of environmental problems is necessary for complete control.

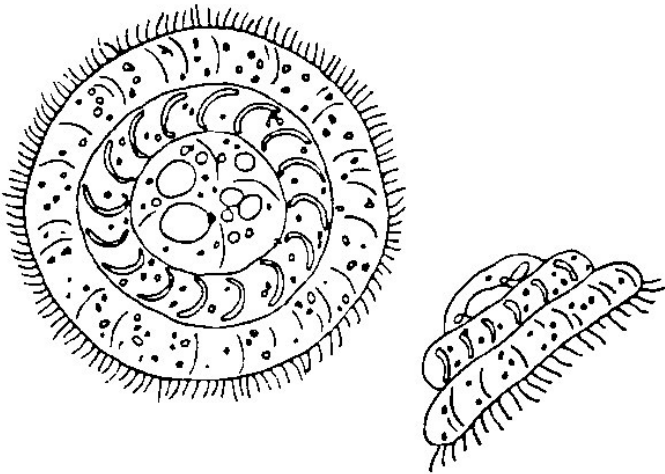


Figure 5.

AMBIPHYRA

Ambiphyra, previously called *Scyphidia*, is a sedentary ciliate that is found on the skin, fins, or gills of host fish. Its cylindrical shape, row of oral cilia, and middle bank of cilia identify *Ambiphyra* (Figure 6). It is common on pond-reared fish, and when present in low numbers (less than five organisms per low power field), it is not a problem. High organic loads and deterioration of water quality are often associated with heavy, debilitating *Ambiphyra* infestations. This parasite can be controlled with one application of any of the treatments listed in Table 1.

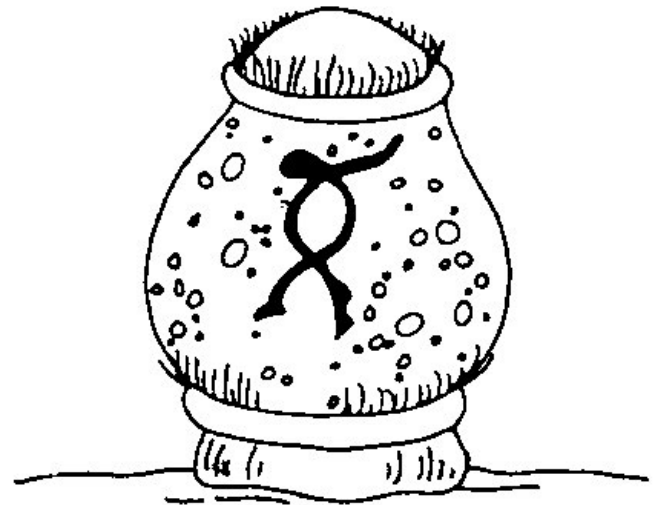


Figure 6.

APIOSOMA

Apiosoma, formerly known as *Glossatella*, is another sedentary ciliate common on pond-reared fish. *Apiosoma* can cause disease if their numbers become excessive. The organism can be found on gills, skin, or fins. The vase-like shape and oral cilia are characteristic (Figure 7). *Apiosoma* can be controlled with one application of one of the treatments from Table 1.

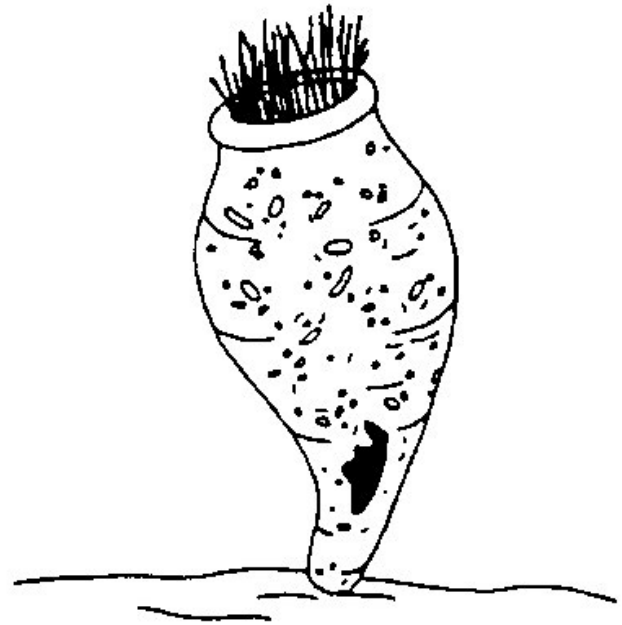


Figure 7.

EPISTYLIS

Epistylis is a stalked ciliate that attaches to the skin or fins of the host. *Epistylis* is of greater concern than many of the ciliates because it is believed to secrete proteolytic (“protein-eating”) enzymes that create a wound, suitable for bacterial invasion, at the attachment site. It is similar in appearance to *Apiosoma* except for the non-contractile long stalk (Figure 8) and its ability to form colonies. In contrast to the other ciliates discussed above, the preferred treatment for *Epistylis* is salt. Fish can be placed into a 0.02% salt solution as an indefinite bath, or a 3% salt dip. More than one treatment may be required to control the problem. For more information, see IFAS Extension Fact Sheet VM-85, “Red Sore Disease” in Game Fish.

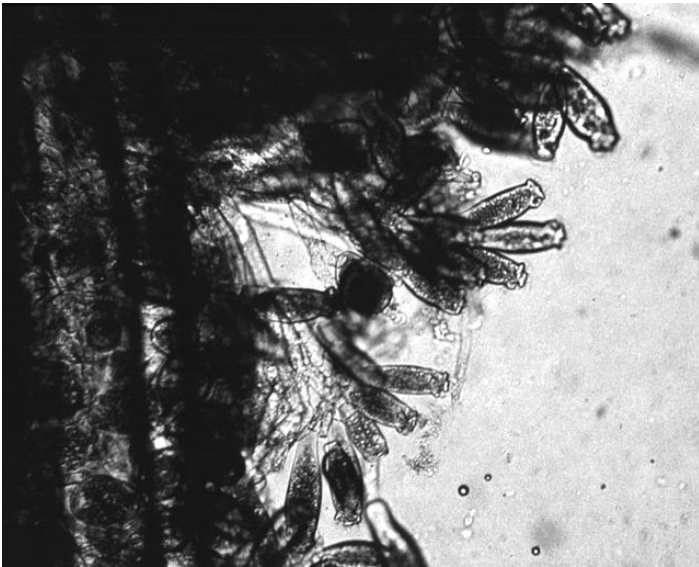

Figure 8.

CAPRINIANA

Capriniana, historically called *Trichophyra*, is a sessile ciliate that attaches to the host’s gills with a sucker. They have characteristic cilia attached to an amorphous-shaped body (Figure 9). In heavy infestations, *Capriniana* can cause respiratory distress in the host. One treatment from a chemical listed in Table 1 should be adequate.

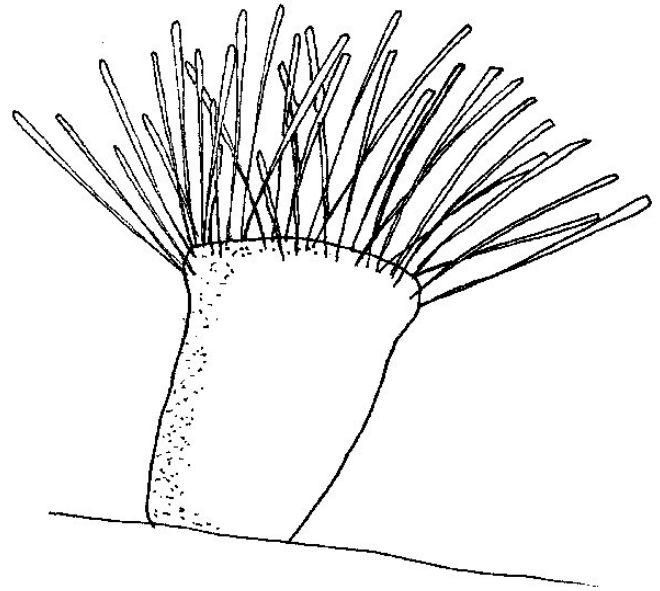


Figure 9.

TREATMENT OF CILIATED PROTOZOAN INFECTIONS

Several chemicals commonly used to control ciliated protozoans in freshwater fish are listed below for your convenience. As stated above, most ciliate infestations respond to one chemical treatment; however, fish that do not improve as expected should be rechecked and retreated if necessary. Overtreatment with chemicals can cause serious damage to fish. The reader is also highly encouraged to read Extension Publication 673 (Mississippi State University), *Calculation of Treatments*, and IFAS Fact Sheet VM-78, *Bath Treatments for Sick Fish*.

Copper sulfate is an excellent compound for use in ponds to control external parasites and algae; however, it is extremely toxic to fish. Its killing action is directly proportional to the concentration of copper ions (Cu^{++}) in the water. As the alkalinity of the water increases, the concentration of copper ions in solution decreases. Consequently, a therapeutic level of copper in water of high alkalinity would be lethal to fish in water of low alkalinity. Conversely, a therapeutic concentration of copper in water of low alkalinity would be insufficient to have the desired action in water of higher alkalinity. For this reason, **the alkalinity of the water to be treated must be known** in order to determine the amount of copper sulfate needed. The amount of copper sulfate needed in mg/L is the total alkalinity (in mg/L) divided by 100. For example, if the total alkalinity in a pond is 100 mg/L, the concentration of copper sulfate needed would be 100/100 or 1 mg/L. If you are unsure how to measure the

alkalinity of your water, or have never used copper sulfate, contact your aquaculture Extension specialist for assistance. Never use copper sulfate in water that has a total alkalinity less than 50 mg/L.

Because of its algicidal activity, copper sulfate can cause dangerous oxygen depletions, particularly in warm weather. Emergency aeration should always be available when copper sulfate is applied to your system or ponds. Copper sulfate should not be run through the biofilter on a recirculation system as it will kill the nitrifying bacteria. If possible, tanks should be taken “off-line” during treatment with copper sulfate. If necessary, clean the biofilter manually to decrease organic debris and residual parasite load. For more information see IFAS Fact Sheet [FA-13](#), *Use of Copper in Aquaculture and Farm Ponds*.

Potassium permanganate is effective against ciliates as well as fungus and external columnaris bacteria, and it can be used in a pond or vat. Multiple treatments with potassium permanganate are not recommended as it can burn gills. Aeration should be available when potassium permanganate is used because it is an algicide and can cause an oxygen depletion. Potassium permanganate at the prescribed dosage (2 mg/L) does not seem to affect the nitrifying bacteria in a biological filter; however, ammonia, nitrite, and pH should be closely monitored following treatment. See also IFAS Fact Sheets [FA-23](#), *The Use of Potassium Permanganate in Fish Ponds*, and [FA-37](#), *Use of Potassium Permanganate to Control External Infections of Ornamental Fish*.

Formalin is an excellent parasiticide for use in small volumes of water such as vats or aquaria. It is not recommended for pond use because it is a strong algicide and chemically removes oxygen from the water. Vigorous aeration should always be provided when formalin is used. See also IFAS Fact Sheet [VM-77](#), *Use of Formalin to Control Fish Parasites*.

Used in proper amounts, salt effectively controls protozoans on the gills, skin, and fins of fish. This is an effective treatment for small volumes of water such as aquaria or tanks. Use in ponds as a treatment is generally not recommended due to the large amount of salt and high cost of treatment that would be needed to be effective. Salt should never be used on fish that navigate by electrical field such as knifefish and elephant nose fish. See also IFAS Fact Sheet [VM-86](#), *The Use of Salt in Aquaculture*.

When using any treatment for fish, a bioassay (a test to determine safe concentration) should be conducted on

a few fish before large numbers of fish are exposed. Fish species can react differently to various concentrations of the chemical; therefore, fish undergoing treatment must be monitored closely for adverse reactions. If the fish negatively react to treatment, the chemical should be flushed immediately from the system, or the fish should be moved to fresh water.

Flagellates

Flagellated protozoans are small parasites that can infect fish externally and internally. They are characterized by one or more flagella that cause the parasite to move in a whip-like or jerky motion. Because of their small size, their movement, observed at 200 or 400x magnification under the microscope, usually identifies flagellates. Common flagellates that infest fish are given below.

HEXAMITA /SPIRONUCLEUS

Hexamita is a small (3 -- 18 m) intestinal parasite commonly found in the intestinal tract of freshwater fish (Figure 10). Sick fish are extremely thin and the abdomen may be distended. The intestines may contain a yellow mucoïd (mucus-like) material. Recent taxonomic studies have labeled the intestinal flagellate of freshwater angelfish as *Spirionucleus*. *Hexamita* or *Spirionucleus* can be diagnosed by making a squash preparation of the intestine and examining it at 200 or 400x magnification. The flagellates can be seen where the mucosa (intestinal lining) is broken. They move by spiraling and in heavy infestations, they will be too numerous to be overlooked.

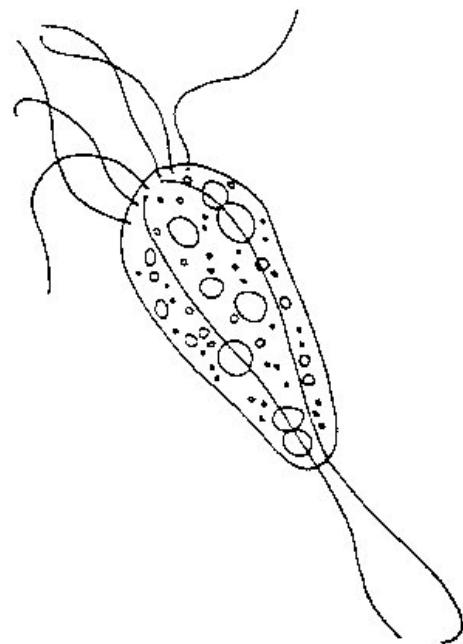


Figure 10.

The recommended treatment for *Hexamita* / *Spiroucleus* is metronidazole (Flagyl). Metronidazole can be administered in a bath at a concentration of 5 mg/L (18.9 mg/gallon) every other day for three treatments. Medicated feed is even more effective at a dosage of 50 mg/kg body weight (or 10 mg/gm food) for five consecutive days. See also IFAS Fact Sheet VM-67, *Management of Hexamita in Ornamental Cichlids*.

ICHTHYOBODO

Ichthyobodo, formerly known as *Costia*, is a commonly encountered external flagellate (Figure 11). *Ichthyobodo*-infected fish secrete copious amounts of mucus. Mucus secretion is so heavy that catfish farmers popularly refer to the disease as “blue slime disease”. Infected angelfish also produce excessive mucus that can give dark colored fish a gray or blue coloration along the dorsal body wall. Infected fish flash and lose condition, often characterized by a thin, unthrifty appearance. *Ichthyobodo* can be located on the gills, skin, and fins, however, it is difficult to identify because of its small size. The easiest way to identify *Ichthyobodo* is by its corkscrew swimming pattern. With a good microscope, the attached organism can be seen at 400x magnification. The organism is easily controlled using one application of one of the treatments listed in Table 1.

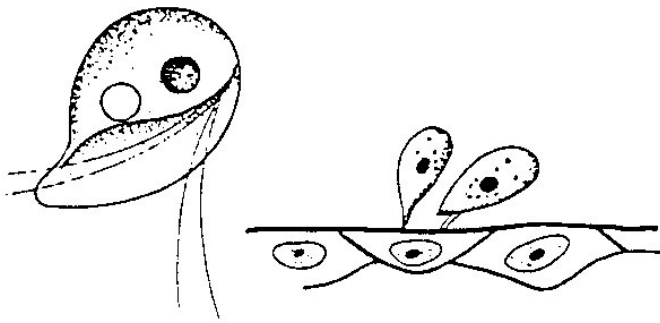


Figure 11.

PISCINOODINIUM

Piscinoodinium is a sedentary flagellate that attaches to the skin, fin, and gills of fish. The common name for *Piscinoodinium* infection is “Gold Dust” or “Velvet” Disease. The parasite has an amber pigment, visible on heavily infected fish. Affected fish will flash, go off feed, and die. *Piscinoodinium* is most pathogenic to young fish. The life cycle of this parasite can be completed in 10--14 days at 73--77°F (Figure 12), but lower temperatures can slow the life cycle. Also, the cyst stage is highly resistant to chemical treatment. Therefore, several applications of a treatment (Table 1) may be necessary to eliminate the parasite. For non-food species, chloroquin (10mg/L prolonged bath) has been reported to be efficacious. For more information, see

IFAS Fact Sheet VM-90, *Amyloodinium Infections of Marine Fish*, the marine counterpart to *Piscinoodinium*.

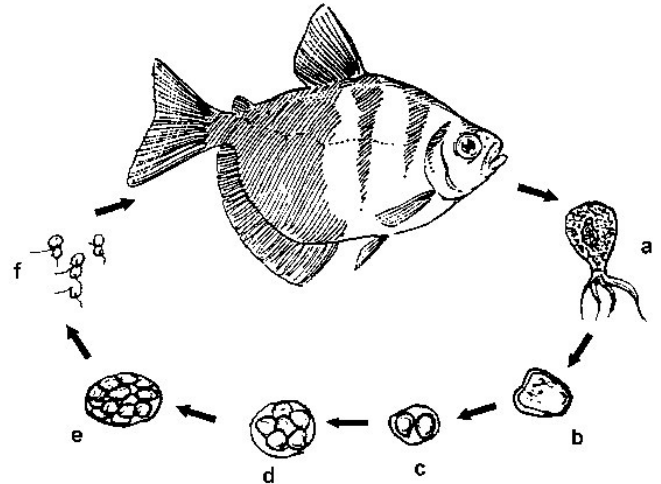


Figure 12.

CRYPTOBIA

Cryptobia is a flagellated protozoan common in cichlids. They are often mistaken for *Hexamita* as they are similar in appearance. However, *Cryptobia* are more drop-shaped, with two flagella, one on each end. Also, *Cryptobia* “wiggles” in a dart-like manner, whereas *Hexamita* “spirals”. *Cryptobia* typically is associated with granulomas (Figure 13), in which the fish “walls off” the parasite. These parasites have been observed primarily in the stomach, but may be present in other organs. Fish afflicted with *Cryptobia* may become thin, lethargic and develop a dark skin pigmentation. A variety of treatments are presently being studied with limited success. Nutritional management has proven to take an active role in its control.

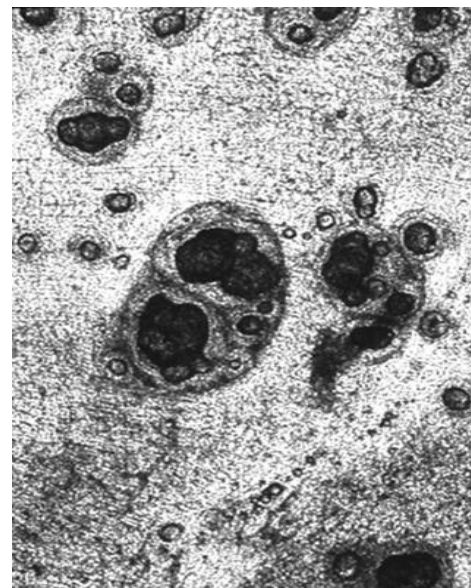

Figure 13.

Myxozoa

Myxozoa are parasites that are widely dispersed in native and pond-reared fish populations. Most infections in fish create minimal problems, but heavy infestations can become serious, especially in young fish. Myxozoans are parasites affecting a wide range of tissues. They are an extremely abundant and diverse group of organisms, speciated by spore shape and size. Spores can be observed in squash preparations of the affected area at 200 or 400x magnification or by histologic sections.

Clinical signs vary, depending on the target organ. For example, fish may have excess mucus production, observed with *Henneguya* (Figure 14) infections.

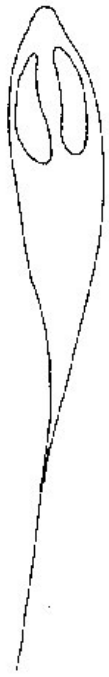

Figure 14.

White or yellowish nodules may appear on target organs. Chronic wasting disease is common among intestinal myxozoans such as with *Chloromyxum*. “Whirling disease” caused by *Myxobolus cerebralis* has been a serious problem in salmonid culture. Elimination of the affected fish and disinfection of the environment is the best control of myxozoans. There are no established remedies for fish. Spores can survive over a year, so disinfection is mandatory for eradication. See IFAS Fact Sheet [VM-87, Sanitation Practices for Aquaculture Facilities](#).

Microsporidia

Microsporidians are intracellular parasites that require host tissue for reproduction. Fish acquire the parasite

by ingesting infective spores from infected fish or food. Replication within spores (schizogony) causes enlargement of host cells (hypertrophy). Infected fish may develop small tumor-like masses in various tissues. Diagnosis is confirmed by finding spores in affected tissues, either in wet mount preparations, or in histologic sections.

Clinical signs depend on the tissue infected and can range from no visible lesions to mortalities. In the most serious cases, cysts enlarge to a point that organ function is impaired and severe morbidity and/or mortality results. A common microsporidian infection is *Pleistophora*, which infects skeletal muscle (Figure 15).

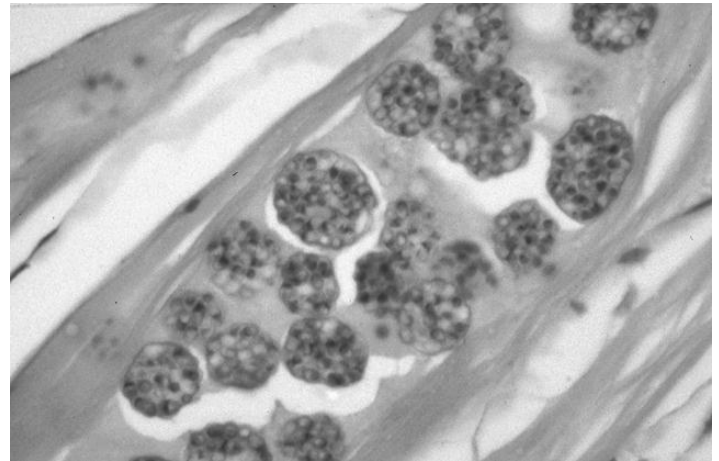


Figure 15.

There is no treatment for microsporidian infections in fish. Spores are highly resistant to environmental conditions and can survive for long periods. Elimination of the infected stock and disinfection of the environment is recommended.

Coccidia

Coccidia are intracellular parasites described in a variety of wild-caught and cultured fish (Figure 16). Their role in the disease process is poorly understood, but there is increasing evidence that they are potential pathogens. The most common species encountered in fish are intestinal infections. Inflammation and death of the tissue can occur, which can affect organ function. Other infection sites include reproductive organs, liver, spleen, and swim bladder.

Clinical signs depend on target organ affected but may include general malaise, poor reproductive capacity, and chronic weight loss. A definitive diagnosis of tissue coccidia should be completed with histologic or electron microscopy. Several compounds have been used to control coccidiosis with some success; however, consultation with an experienced fish health professional is recommended.

Maintaining a proper environment and reducing stress appear to be important in preventing coccidia outbreaks in cultured fish.

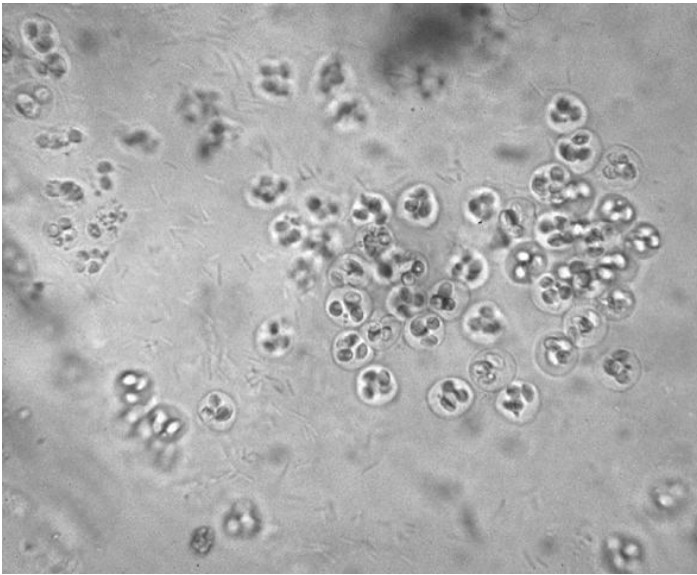


Figure 16.

Monogenean Trematodes

Monogenean trematodes, also called flatworms or flukes, commonly invade the gills, skin, and fins of fish. Monogeneans have a direct life cycle (no intermediate host) and are host- and site-specific. In fact, some adults will remain permanently attached to a single site on the host.

Freshwater fish infested with skin-inhabiting flukes become lethargic, swim near the surface, seek the sides of the pool or pond, and their appetite dwindles. They may be seen rubbing the bottom or sides of the holding facility (flashing). The skin where the flukes are attached shows areas of scale loss and may ooze a pinkish fluid. Gills may be swollen and pale, respiration rate may be increased, and fish will be less tolerant of low oxygen conditions. “Piping”, gulping air at the water surface, may be observed in severe respiratory distress. Large numbers (>10 organisms per low power field) of monogeneans on either the skin or gills may result in significant damage and mortality. Secondary infection by bacteria and fungus is common on tissue with monogenean damage.

Gyrodactylus and *Dactylogyrus* are the two most common genera of monogeneans that infect freshwater fish (Figure 17). They differ in their reproductive strategies and their method of attachment to the host fish. *Gyrodactylus* have no eyespots, two pairs of anchor hooks, and are generally found on the skin and fins of fish. They are live bearers (viviparous) in which the adult parasite can be seen with a

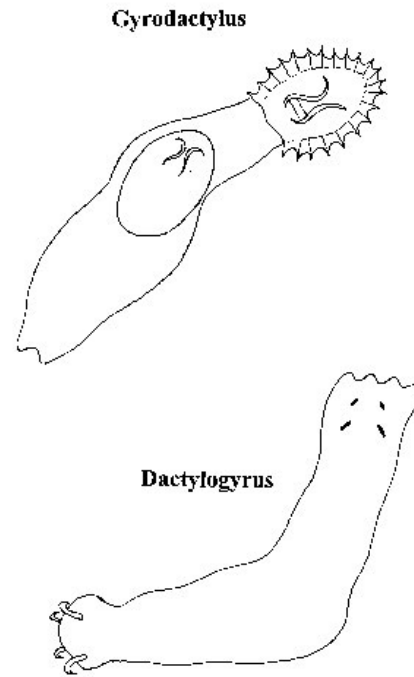


Figure 17.

fully developed embryo inside the adult’s reproductive tract. This reproductive strategy allows populations of *Gyrodactylus* to multiply quickly, particularly in closed systems where water exchange is minimal.

Dactylogyrus prefers to attach to gills. They have two to four eyespots, one pair of large anchor hooks, and are egg layers. The eggs hatch into free-swimming larvae and are carried to a new host by water currents and their own ciliated movement. The eggs can be resilient to chemical treatment, and multiple applications of a treatment are usually recommended to control this group of organisms.

Treatment of monogeneans is usually not satisfactory unless the primary cause of increased fluke infestations is found and alleviated. The treatment of choice for freshwater fish is formalin, administered as a short-term or prolonged bath (Table 1). Fish that are sick do not tolerate formalin well, so they need to be carefully monitored during treatment. Potassium permanganate can also be effective in controlling monogeneans. For more information, see IFAS Fact Sheet FA-28, *Monogenean Trematodes*.

Digenean Trematodes

Digenean trematodes have a complex life cycle involving a series of hosts (Figure 18). Fish can be the primary or intermediate host depending on the digenean species. They are found externally or internally, in any organ. For the majority of digenean trematodes, pathogenicity to the host is limited.

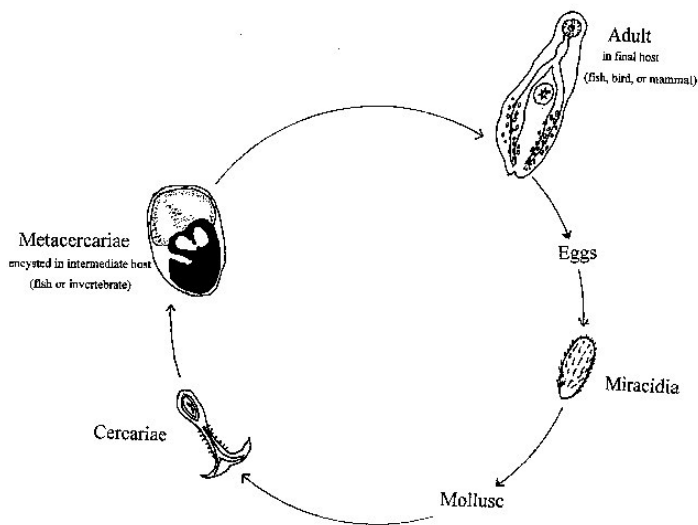


Figure 18.

The life stage most commonly observed in fish is the metacercaria, which encysts in fish tissues (Figure 19). Again, metacercaria that live in fish rarely cause major problems. However, in the ornamental fish industry, digenetic trematodes from the family Heterophyidae, have been responsible for substantial mortalities in pond-raised fish. These digeneans become encysted into gill tissue and respiratory distress is eminent.

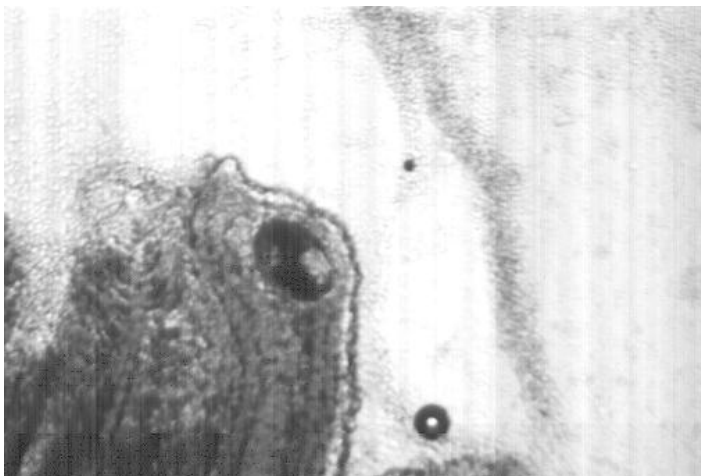


Figure 19.

Another example of a metacercaria that could cause problems in cultured fish is the genus *Posthodiplostomum* or the white grub. This has caused mortalities in baitfish, but usually the only negative effect is reduced growth rate, even when the infection rate is high. In cases where mortalities occur, there are unusually high numbers in the eye, head, and throughout the visceral organs.

Another fluke is *Clinostomum*, often called yellow grub. It is a large trematode and although it does not cause any

major problems for fish, it is readily seen and will make fish unmarketable for aesthetic reasons.

The best control of digenean trematodes is to break the life cycle of the parasite. Elimination of the first intermediate host, the freshwater snail is often recommended. Copper sulfate in ponds has been used with limited success and is most effective against snails when applied at night, due to their nocturnal feeding activity. For Florida ornamental fish growers a chemical for snail control, Bayluscide, is available. This is a Restricted Use Pesticide and access to it is controlled. For more information, contact your aquaculture Extension specialist or the University of Florida Tropical Aquaculture Laboratory in Ruskin, Florida.

Nematodes

Nematodes, also called roundworms, occur worldwide in all animals. They can infect all organs of the host, causing loss of function of the damaged area. Signs of nematodiasis include anemia, emaciation, unthriftiness and reduced vitality. Three common nematodes affecting fish are described.

Camillanus

Camillanus is easily recognized as a small thread-like worm protruding from the anus of the fish. Control of this nematode in non-food fish is with fenbendazole, a common antihelminthic. Fenbendazole can be mixed with fish food (using gelatin as a binder) at a rate of 0.25% for treatment. It should be fed for three days, and repeated in three weeks.

Capillaria

Capillaria is a large roundworm commonly found in the gut of angelfish (Figure 20), often recognized by its double operculated eggs in the female worm (Figure 21). Heavy infestations are associated with debilitated fish, but a few worms per fish may be benign. Fenbendazole is recommended for treatment (see above).

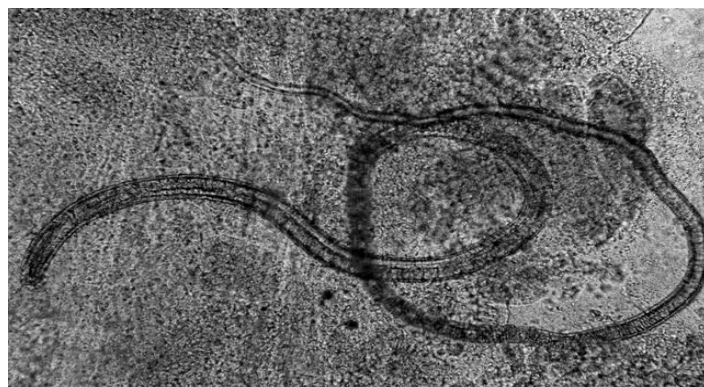


Figure 20.

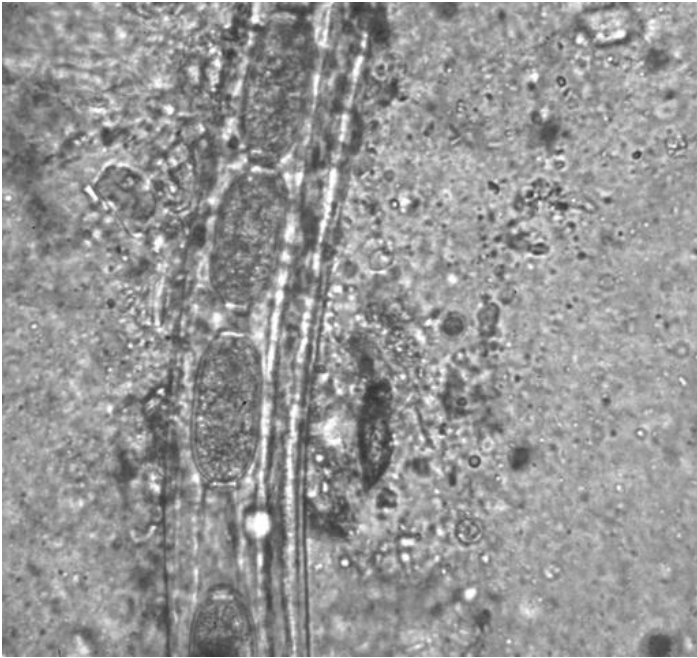


Figure 21.

Eustrongylides

Eustrongylides is a nematode that uses fish as its intermediate host. The definitive host is a wading bird, a common visitor to ponds. The worm encysts in the peritoneum or muscle of the fish and appears to cause little damage. Because of the large size of the worms (Figure 22), infected fish may appear unsuitable for retail sales. Protecting fish from wading birds and eliminating the intermediate host, the oligochaete or Tubifex (soft-bodied worms), are the best means to prevent infection.

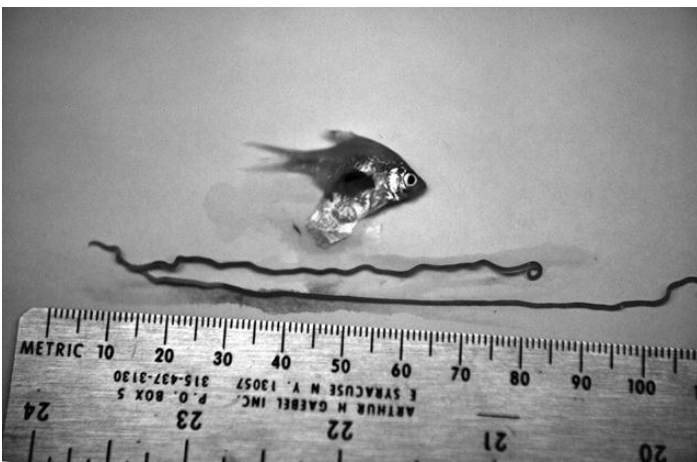


Figure 22.

Cestodes

Cestodes, also called tapeworms, are found in a wide variety of animals, including fish (Figure 23). The life cycle of cestodes is extremely varied with fish used as the primary

or intermediate host. Cestodes infect the alimentary tract, muscle or other internal organs. Larval cestodes called plerocercoids are some of the most damaging parasites to freshwater fish. Plerocercoids decrease carcass value if present in muscle, and impair reproduction when they infect gonadal tissue. Problems also occur when the cestode damages vital organs such as the brain, eye or heart.

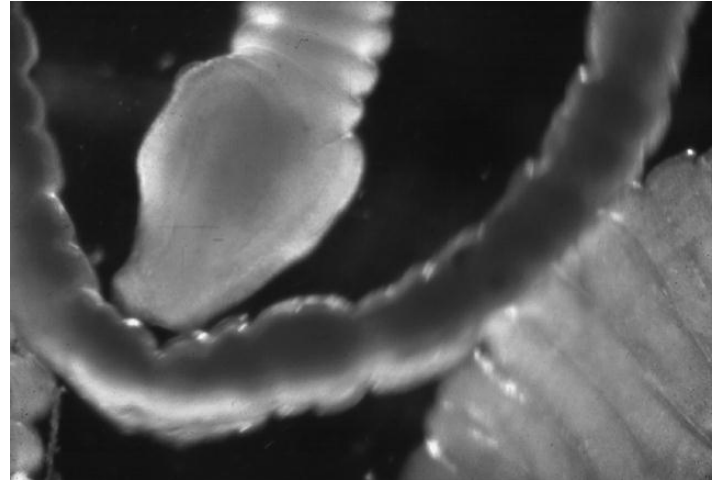


Figure 23.

One of the most serious adult cestodes that affect fish is the Asian tapeworm, *Bothriocephalus acheilognathi*. It has been introduced to the United States with grass carp and has caused serious problems with bait minnow producers.

Praziquantel at 2 -- 10 mg/L for 1 to 3 hours in a bath is effective in treating adult cestode infections in ornamental fish. At this time, there is no treatment that can be used for food fish. Also, there is no successful treatment for plerocercoids. Ponds can be disinfected to eradicate the intermediate host, the copepod.

Parasitic Crustacea

Parasitic crustacea are increasingly serious problems in cultured fish and can impact wild populations. Most parasitic crustacea of freshwater fish can be seen with the naked eye as they attach to the gills, body and fins of the host. Three major genera are discussed below.

Ergasilus

Ergasilus (Figure 24) are often incidental findings on wild or pond-raised fish and probably cause few problems in small numbers. However, their feeding activity causes severe focal damage and heavy infestations can be debilitating. Most affect the gills of freshwater fish, commonly seen in warm weather. A 3% salt dip, followed by 0.2 %-prolonged bath for three weeks, may be effective in eliminating this parasite.

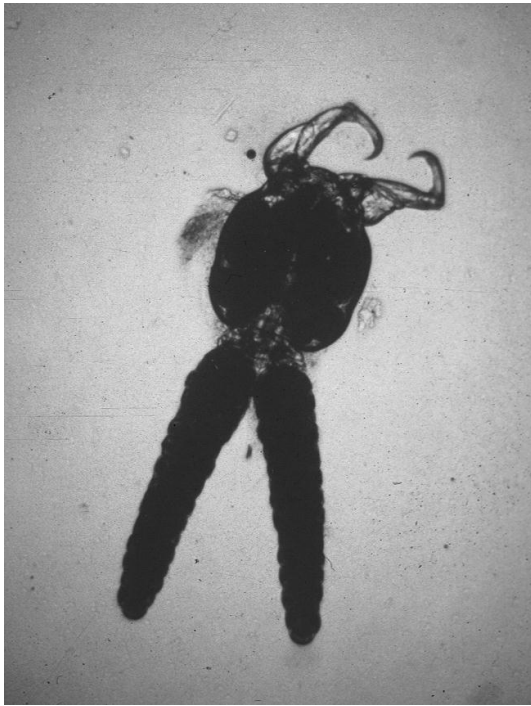


Figure 24.

Lernaea

Lernaea, also known as anchor worm (Figure 25), is a common parasite of goldfish and koi, especially during the summer months. The copepod attaches to the fish, mates, and the male dies. The female then penetrates under the skin of the fish and differentiates into an adult. Heavy infections lead to debilitation and secondary bacterial or fungal infections. Removal of the parasite by hand with forceps may control lernaeid infestations with careful monitoring of the wound. A 3% salt dip followed by 0.2%-prolonged immersion has been used to effectively control *Lernaea* in goldfish and koi ponds.

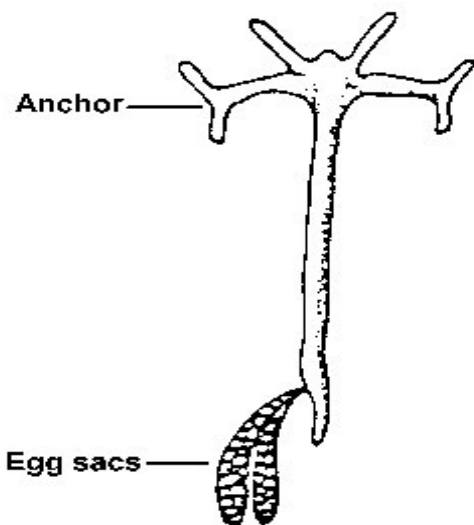


Figure 25.

Argulus

Argulus or fish louse is a large parasite (Figure 26) that attaches to the external surface of the host and can be easily seen with the unaided eye. *Argulus* is uncommon in freshwater aquarium fish but may occur if wild or pond-raised fish are introduced into the tank. It is especially common on goldfish and koi.

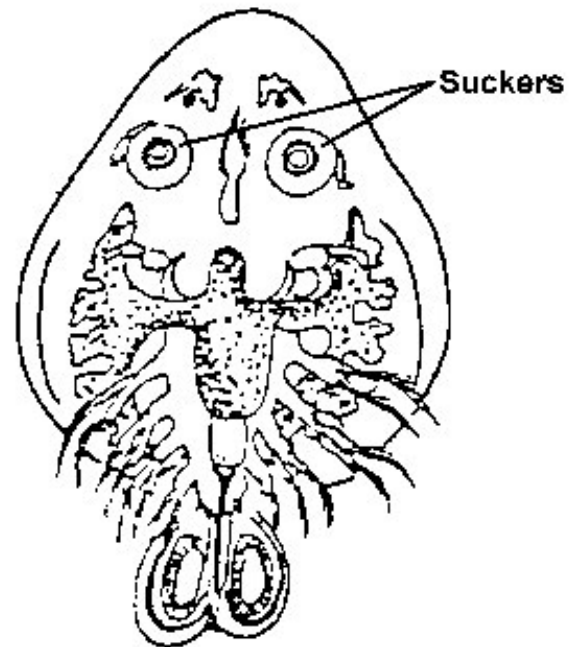


Figure 26.

Individual parasites can be removed from fish with forceps, but this does not eliminate parasites in the environment. A prolonged immersion of 0.02 - 0.2% salt may control re-infection to the fish host.

Leeches

Leeches are occasionally seen in wild and pond-raised fish. They have a direct life cycle with immature and mature worms being parasitic on host's blood. Pathogenesis varies with number and size of worms and duration of feeding. Heavily infested fish often have chronic anemia. Fish may develop secondary bacterial and fungal infections at the attachment site.

Leeches resemble trematodes but are much larger and have anterior and posterior suckers (Figure 27). Dips in 3% saltwater are effective in controlling leeches. Ponds with heavy leech infestation require drainage, treatment with chlorinated lime, followed by several weeks of drying. This will destroy the adults and their cocoons containing eggs.

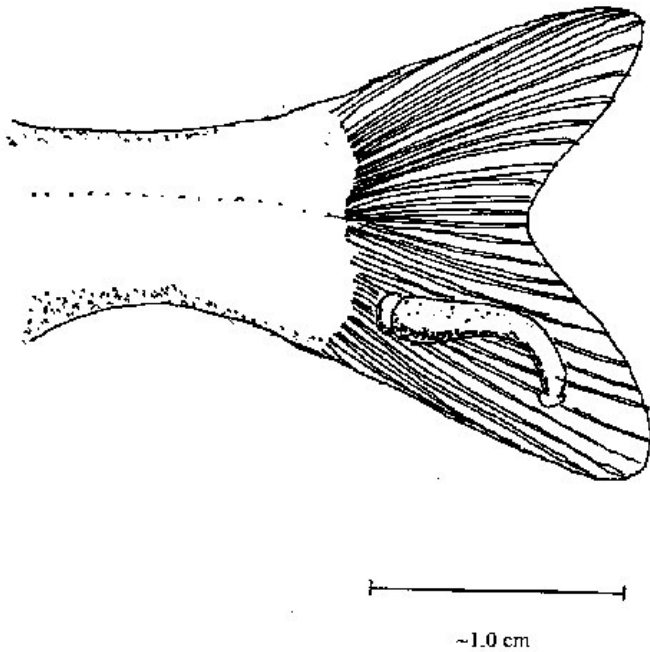


Figure 27.

Conclusion

Most fish health problems occur because of environmental problems: poor water quality, crowding, dietary deficiencies, or “stress”. The best cure for any fish health problem is prevention. Good water quality management and proper fish husbandry techniques will eliminate most parasites described here. Information concerning basic fish culture, pond management, water quality, and economics is available in aquaculture extension circulars from your Cooperative Extension Service agent.

Acknowledgements

The authors wish to especially thank Chris Tilghman and Peggy Reed for their artistic contributions to this circular, and Roy Yanong for the photo of *Coccidia*.

Table 1.

Chemical treatments for the control of external ciliates. "X" indicates that the chemical should not be used for this type of treatment.

| | | | | |
|------------------------|---|------------------------------------|---------------------------------------|--------------------------------------------------------------------------------|
| Copper sulfate | X | X | | total alkalinity/100 (up to 2.5 mg/L). Do not use if total alkalinity < 50mg/L |
| Potassium permanganate | X | | 10 mg/L, 30 min | 2 mg/L |
| Formalin | X | | 150--250 mg/L, 30 min | 15--25 mg/L (2 drops/gallon or 1 mL/10 gallons) |
| Salt | | 3%, Duration is species dependent. | 1%, 30 min to 1 hr, species dependent | 0.02--0.2% |